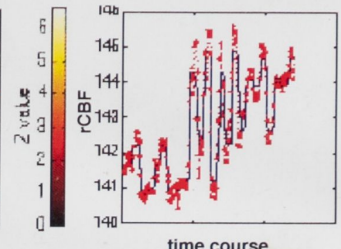
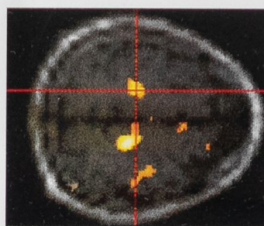
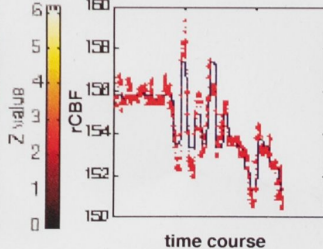
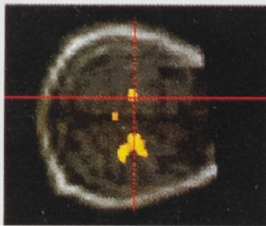
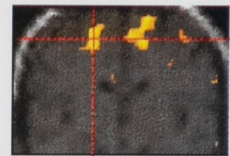
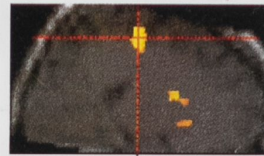




# fMRI after Ulnar Nerve Surgical Transfer (A.C.)

## RIGHT LEG MOVEMENT

Z>3.09



leg: x= -14  
y= -22  
z= +68

hand: x= -20  
y= -20  
z= +56

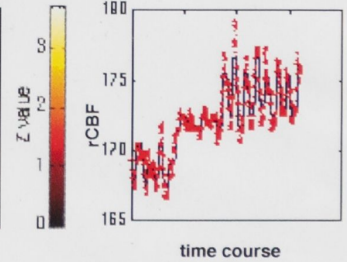
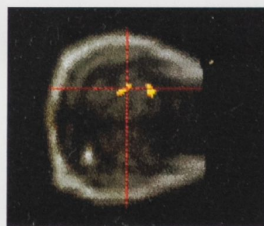
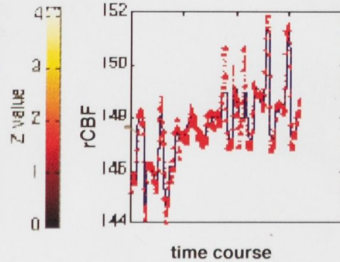
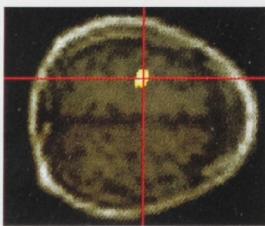


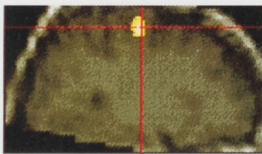
fMRI - SPM96

HSR-Milano

# fMRI after Ulnar Nerve Surgical Transfer (A.C.)

## RIGHT WHOLE ARM MOVEMENT

Z>3.09



arm : x= -28  
y= -14  
z= +60

leg : x= -20  
y= -28  
z= +76

fMRI - SPM96

HSR-Milano

Studio Medico Risonanza Magnetica Corticale della Riattivazione:  
area del movimento della gamba tramite l'area del movimento della mano

Ospedale San Raffaele di Milano